

International Journal of Recent Trends in Engineering, Vol 2, No. 4, November 2009  
**EXUDATES DETECTION AND CLASSIFICATION IN DIABETIC  
RETINOPATHY IMAGES BY TEXTURE SEGMENTATION METHODS**

Ms. P.N. Jebarani Sargunar, Asst. Professor, Dept. of IT, SSN College of Engineering, Kalavakkam-603110.  
India, Email: [jebaranipn@ssn.edu.in](mailto:jebaranipn@ssn.edu.in)  
Dr.R.Sukanesh, Professor, ECE Dept., Thiagarajar College of Engineering, Madurai-15.India.  
[drsukanesh-2003@yahoo.com](mailto:drsukanesh-2003@yahoo.com)

**ABSTRACT:** Diabetic Retinopathy(DR) refers to the presence of typical retinal micro vascular lesions in persons with diabetics. When the disease is at the early state, a prompt diagnosis may help in preventing irreversible damages to the diabetic eye. If the exudates are closer to macula, then the situation is critical. In this paper the minimum distance of exudates from macula is calculated. This paper proposes tool for the early detection of Diabetic Retinopathy using fuzzy c-means clustering, fractal techniques and morphological transformations. The proposed system involves preprocessing the retinal image for enhancing the information followed by thresholding, optic disk segmentation and classification using fractal measures and clustering techniques. A classification accuracy of 85% is achieved. The proposed method involves less computational requirement and can be applied for real time application

**KEY WORDS:** FCM, Texture Segmentation, Exudates, Digital Image Processing.

### INTRODUCTION

Medical image analysis is one of the research areas that are currently attracting intensive interests of scientists and physicians. It consists of the study of digital images with the objective of providing computational tools that assist quantification and visualization of interesting pathology and anatomical structures. The progress, which has been achieved in this area over recent years, has significantly improved the type of medical care that is available to patients. Physicians can now examine inside the human body to diagnose, treat, monitor changes and plan different mechanisms more successfully than before. The physician can thus obtain decision support, be reassured of repetitive tasks, and consistently receive valuable measurements. However, this is a multidisciplinary task and requires comprehensive knowledge in many disciplines, such as image processing and computer vision, machine learning, pattern recognition and expert systems.

The severe progression of diabetes is one of the greatest immediate challenges to current health care. The number of people afflicted continues to grow at an alarming rate. The World Health Organization expects the number of diabetics to increase from 130 million to 350 million over the next 25 years. However, only one half of the patients are aware of the disease. Diabetes leads to severe late complications including macro and micro vascular changes resulting in heart disease and retinopathy. Diabetic Retinopathy (DR) is a common complication of diabetes and the leading cause of blindness in the working population of western countries.[1-5]. It is a silent disease and may only be recognized by the patient when the changes in the retina have progressed to a level, that treatment is complicated and nearly impossible.[6-12].

A new approach based on mixture models to estimate the image histograms and to obtain a dynamic threshold for each image by Clara in [1]. JAVA-based system, an inexpensive tool that allows display of individual retinal images in four or more windows for simultaneous viewing of multiple modalities has been proposed in [2]. [3] Presents a non invasive transient visual evoked potential phase spectral components periodicity measure based method to classify diabetic retinopathy. Efficient algorithms for the detection of the optic disc and retinal exudates have been presented in [4, 5]. Different properties of the bright lesions and dark lesions, together with bottom up and top-down strategies, are respectively and effectively applied to solve these problems [5]. The boundaries of hemorrhages can be accurately segmented in the post-processing stage as shown in [6]. Multi-class classifier approach has been suggested in [7]. In order to reduce the huge number of parameters that have to be extracted by the ophthalmologist, image-processing methods for the automatic analysis of fundus photographs have been developed [8]. The extraction is done by a multistage model-based approach[9]. The segmentation results are used as input to an overall fuzzy system that produces the final decision outcome. A three-stage approach is applied to detect and classify bright lesions by Zhang Xiaohui and Opas Chutatape [9-11].

SYSTEM DESIGN

A Retinal image is given as the input and the retinal image is preprocessed by local contrast enhancement using mean and variance. The preprocessed image is given for feature extraction where thresholding and optic disk segmentation is done. After segmenting the optic disk, textural features of the affected region are obtained. With the help of such features of image, they can be classified. Pupil dilation is not required. No burden on the ophthalmologists. This would save a significant amount of workload and time for ophthalmologists, allowing them to concentrate their resources on surgery and treatment. The process has two main segmentation steps which are coarse segmentation using Fuzzy C-Means clustering and fine segmentation using Morphological reconstruction.[2,8,10]. Textural features, namely intensity, standard deviation on intensity, hue and adapted edge, were selected for coarse segmentation[4,5,6]. Dilation is used for fine segmentation.[7,10]. Hurst coefficient is used for classification. The detected results are validated by comparing with expert ophthalmologist's hand-drawn ground-truth.

. Various features extracted are:

Statistical Pixel-Level (SPL) Features.

area and perimeter of the structures present in the image.

Shape Features.

Compactness

Texture Features

provide information about the local texture within the region.

Mean- average intensity .

Standard deviation- average contrast.

Relative Smoothness.

Uniformity.

Entropy- measure of randomness.

Fractal measures:

Hurst coefficient.

Distance parameter that calculates the distance of exudates from macula.

Then FCM is used for coarse segmentation and then morphological transformations are used for fine segmentation.

These values are tabulated in Table-1..

Hard exudates are automatically extracted and quantified in several steps. At first, all the vessels are eliminated using morphological techniques, which is followed by local contrast enhancement preprocessing technique. Thresholding is done by applying mixture models. After thresholding both optic disk and exudates appear bright.

Hence optic disk is segmented using watershed transformation. After separating the candidate region the texture features of the candidate region are calculated. The application is tested with small database of retinal images and its accuracy is measured as 85%. The application has to be tested with more number of clinical datasets and images obtained from private ophthalmologists.

RESULTS

The application of automatic image-processing methods to fundus photographs, however, has to deal with the problems of varying image quality, such as contrast and brightness, and that they are characterized by color differences within one image because of inhomogeneous illumination of the eye background and between different images. Class A indicates severity of the case and class D shows less affected cases.

Table-1 Textural features of exudates.

Test Images	Number Of Objects	Area	perimeter	Hurst Coefficient	class
1	8	77	30	2.105	D
2	4	342	75	2.241	C
3	5	24	15	2.201	C
4	9	96	31	2.203	C
5	5	174	64	2.195	C
6	3	140	42	2.204	C
7	2	768	51	2.293	A
8	13	158	84	2.253	B
9	37	777	229	2.301	A
10	2	112	42	2.221	C

GRAPHS:

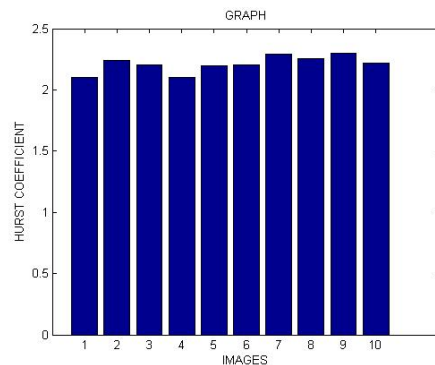
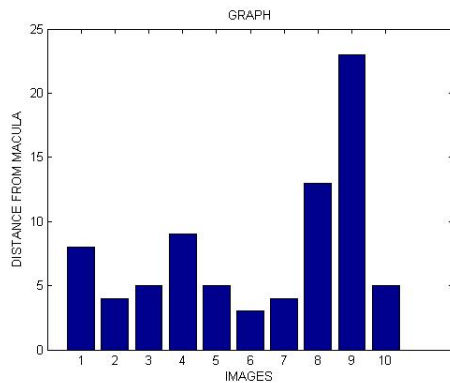


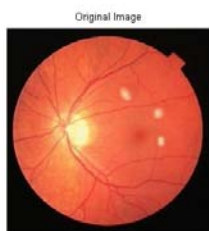
Figure-1 Variation of Hurst coefficient for various images.



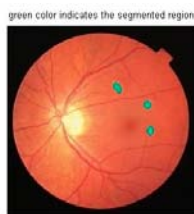
**Figure-2 Variation of Distance from macula for various images.**

The database used to evaluate the method performance is too small to inspire confidence. Therefore the algorithm should be assessed with more images in order to make the results representative of the clinical problem.

#### SNAP SHOTS:



**Figure-3 Original Image**



**Figure-4. Final output Images.**

#### CONCLUSION

In summary, a medical system for the automatic diagnosis of the primary signs of DR and ARMD has been developed. The results demonstrate that the system is well suited to complement the screening of DR helping the ophthalmologists in their daily practice.

#### REFERENCES

- [1]. Clara I. Sanchez, Agustin Mayo, Maria Garcia, Maria I. Lopez and Roberto Hornero "Automatic Image Processing Algorithm to Detect Hard Exudates based on Mixture Models" - *Proceedings of the 28th IEEE EMBS Annual International Conference New York City, USA, Aug 30-Sept 3, 2006*
- [2]. B. Raman, M. Wilson, I. Benche and P. Soliz "A JAVA-based system for Segmentation and Analysis of Retinal Images" - *proceedings of the 16th IEEE symposium on Computer Based Medical Systems (CBMS '03)*
- [3]. Thomas Walter, Jean- Claude Klein, Pascale Massin, and Ali Erginary "A Contribution of Image Processing to the Diagnosis of Diabetic Retinopathy—Detection of Exudates in Color Fundus Images of the Human Retina." - *IEEE transactions on medical imaging, Vol. 21, No. 10, October 2002*
- [4]. Xiaohui Zhang, Opas Chutatape "Top-down and Bottom-up Strategies in Lesion Detection of Background Diabetic Retinopathy" - *Proceedings of the 2005 IEEE Computer Society Conference on Computer Vision and Pattern Recognition (CVPR'05)*
- [5]. XU Jin, HU Guangshu, HUANG Tianna, HUANG Houbin CHEN Bin "The Multifocal ERG in Early Detection of Diabetic Retinopathy" - *Proceedings of the 2005 IEEE Engineering in Medicine and Biology 27th Annual Conference Shanghai, China, September 1-4, 2005*
- [6]. G.Zahlmann, B. Kachner, I. Ugi, D. Schumann, A. Wegner "Hybrid Fuzzy Image Processing for Situation Assessment. A Knowledge-Based system for Early Detection of Diabetic Retinopathy" - *IEEE Engineering in medicine and biology 0739-5175/OO/SIO.OO~ 2000 IEEE January/February 2000*
- [7]. Zhang Xiaohui, Opas Chutatape "Detection and classification of bright lesions in color fundus images" - *2004 International Conference on Image Processing (ICIP)*
- [8]. Akara Sopharak and Bunyarit Uyyanonvara, "Automatic Exudates Detection From Non-Dilated Diabetic Retinopathy Retinal Images Using FCM Clustering", WACBE World Congress on Bioengineering 2007, Bangkok, THAILAND
- [9] Iqbal. M. I, Aibinu. A. M, Gubbal. N. S, and Khan. A, "Automatic Diagnosis Of Diabetic Retinopathy Using Fundus Images", Masters Thesis, Blekinge Institute of Technology, Sweden, October 2006
- [10] Anantha Vidya Sagar, S. Balasubramaniam, and V. Chandrasekaran, "A Novel Integrated Approach using Dynamic Thresholding and Edge Detection (IDTED) for Automatic Detection of Exudates in Digital Fundus Retinal Images", Proc. of the International Conference on Computing: Theory and Applications, IEEE 2007.
- [11]. Niemeijer, M.; Abramoff, M.D.; van Ginneken, B" **Information Fusion for Diabetic Retinopathy CAD in Digital Color Fundus Photographs" *Medical Imaging, IEEE Transactions on* Volume 28, Issue 5, May 2009 Page(s):775 - 785**